

Distribution of the Maxillary Artery as It Relates to Sinus Floor Augmentation

75

Nicolas Elian, DDS¹/Stephan Wallace, DDS²/Sang-Choon Cho, DDS, MSc³/
Ziad N. Jalbout, DDS⁴/Stuart Froum, DDS⁵

Purpose: Knowledge of the blood supply to the sinus is of importance in sinus augmentation, both as it pertains to vascularization of the sinus graft and as its location relates to the position of the required lateral osteotomy. The purpose of this study was to investigate the distribution of the endosseous branches of the maxillary artery in the area of the proposed lateral window. **Materials and Methods:** Fifty computerized tomographic (CT) scans from 625 available patients undergoing sinus augmentation surgery at the New York University Department of Implant Dentistry were chosen at random for evaluation. In those cases where the maxillary artery could be identified, measurements were taken to determine the distance between the alveolar crest and the lower border of the vessel. **Results:** The vessel was radiographically identified in 51.4% of right sinuses and 54.3% of left sinuses in the 50 CT scans. The average height of the artery from the alveolar crest was 16 mm (\pm 3.5 mm). **Discussion and Conclusions:** Because of its location, the intraosseous artery has the potential to cause bleeding complications in approximately 20% of normally positioned lateral window osteotomies. Although a previous anatomic study on cadavers identified the vessel in 100% of the specimens, it could only be visualized in 53% of the CT scans in the present series. INT J ORAL MAXILLOFAC IMPLANTS 2005;20:784-787

Key words: maxillary artery, sinus floor augmentation

The lack of sufficient bone height and bone of poor quality are common deterrents to the placement of root-form implants in the edentulous posterior maxilla. Sinus augmentation has evolved into a predictable surgical modality for increasing the exist-

ing height with bone of sufficient quality to allow for the successful placement of dental implants.^{1,2} The procedure, which was first published by Boyne³ in 1980, has been modified to include both crestal^{4,5} and lateral window techniques.^{6,7}

When performing an osteotomy in the lateral wall of the sinus, it is possible to violate the integrity of the vascular supply in the lateral bony wall, resulting in intraoperative bleeding that may be mild to severe in nature. Solar and associates⁸ investigated the blood supply to the lateral wall of the sinus. Their anatomic study of cadavers showed the presence of the endosseous branch of the posterior superior alveolar artery in the lateral wall in 100% of their specimens. Formed by an anastomosis of the infraorbital artery and the posterior superior alveolar artery, this vessel was located an average distance of 18.9 mm (\pm 2.82 mm) from the alveolar crest. The purpose of this study was to determine if the presence of this artery could be detected utilizing computerized tomographic (CT) scans taken prior to sinus elevation surgery. This knowledge could be significant in avoiding this artery at the time of lateral window surgery.

¹Director, Assistant Professor, Ashman Department of Implant Dentistry, New York University College of Dentistry, New York, New York.

²Clinical Associate Professor, Ashman Department of Implant Dentistry, New York University College of Dentistry, New York, New York.

³Associate Director of Clinical Research, Clinical Assistant Professor, Ashman Department of Implant Dentistry, New York University College of Dentistry, New York, New York.

⁴Instructor, Ashman Department of Implant Dentistry, New York University College of Dentistry, New York, New York.

⁵Director of Clinical Research, Clinical Professor, Ashman Department of Implant Dentistry, New York University College of Dentistry, New York, New York.

Correspondence to: Dr Nicolas Elian, 2185 Lemoine Avenue, Suite 1K, Fort Lee, NJ 07024. Fax: +201 592 5221. E-mail: nickellian@aol.com

Distribution of the Maxillary Artery as It Relates to Sinus Floor Augmentation

Nicolas Elian, DDS¹/Stephan Wallace, DDS²/Sang-Choon Cho, DDS, MSc³/
Ziad N. Jalbout, DDS⁴/Stuart Froum, DDS⁵

Purpose: Knowledge of the blood supply to the sinus is of importance in sinus augmentation, both as it pertains to vascularization of the sinus graft and as its location relates to the position of the required lateral osteotomy. The purpose of this study was to investigate the distribution of the endosseous branches of the maxillary artery in the area of the proposed lateral window. **Materials and Methods:** Fifty computerized tomographic (CT) scans from 625 available patients undergoing sinus augmentation surgery at the New York University Department of Implant Dentistry were chosen at random for evaluation. In those cases where the maxillary artery could be identified, measurements were taken to determine the distance between the alveolar crest and the lower border of the vessel. **Results:** The vessel was radiographically identified in 51.4% of right sinuses and 54.3% of left sinuses in the 50 CT scans. The average height of the artery from the alveolar crest was 16 mm (\pm 3.5 mm). **Discussion: and Conclusions:** Because of its location, the intraosseous artery has the potential to cause bleeding complications in approximately 20% of normally positioned lateral window osteotomies. Although a previous anatomic study on cadavers identified the vessel in 100% of the specimens, it could only be visualized in 53% of the CT scans in the present series. INT J ORAL MAXILLOFAC IMPLANTS 2005;20:784-787

Key words: maxillary artery, sinus floor augmentation

The lack of sufficient bone height and bone of poor quality are common deterrents to the placement of root-form implants in the edentulous posterior maxilla. Sinus augmentation has evolved into a predictable surgical modality for increasing the exist-

ing height with bone of sufficient quality to allow for the successful placement of dental implants.^{1,2} The procedure, which was first published by Boyne³ in 1980, has been modified to include both crestal^{4,5} and lateral window techniques.^{6,7}

When performing an osteotomy in the lateral wall of the sinus, it is possible to violate the integrity of the vascular supply in the lateral bony wall, resulting in intraoperative bleeding that may be mild to severe in nature. Solar and associates⁸ investigated the blood supply to the lateral wall of the sinus. Their anatomic study of cadavers showed the presence of the endosseous branch of the posterior superior alveolar artery in the lateral wall in 100% of their specimens. Formed by an anastomosis of the infraorbital artery and the posterior superior alveolar artery, this vessel was located an average distance of 18.9 mm (\pm 2.82 mm) from the alveolar crest. The purpose of this study was to determine if the presence of this artery could be detected utilizing computerized tomographic (CT) scans taken prior to sinus elevation surgery. This knowledge could be significant in avoiding this artery at the time of lateral window surgery.

¹Director, Assistant Professor, Ashman Department of Implant Dentistry, New York University College of Dentistry, New York, New York.

²Clinical Associate Professor, Ashman Department of Implant Dentistry, New York University College of Dentistry, New York, New York.

³Associate Director of Clinical Research, Clinical Assistant Professor, Ashman Department of Implant Dentistry, New York University College of Dentistry, New York, New York.

⁴Instructor, Ashman Department of Implant Dentistry, New York University College of Dentistry, New York, New York.

⁵Director of Clinical Research, Clinical Professor, Ashman Department of Implant Dentistry, New York University College of Dentistry, New York, New York.

Correspondence to: Dr Nicolas Elian, 2185 Lemoine Avenue, Suite 1K, Fort Lee, NJ 07024. Fax: +201 592 5221. E-mail: nickelian@aol.com

Fig 1 (Left) Measurement of distance from the lower border of the artery to the alveolar crest.

Fig 2 (Right) Preoperative CT scan view of the intraosseous artery through the lateral wall of the maxillary sinus.

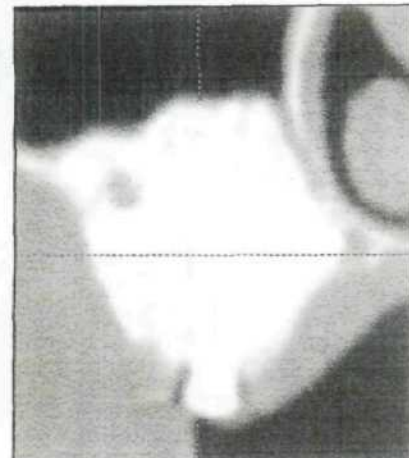
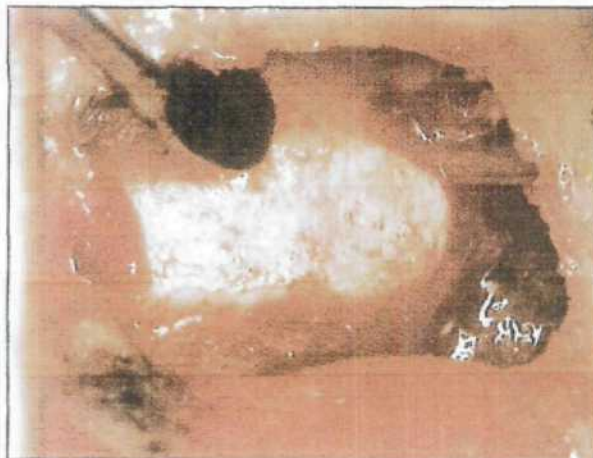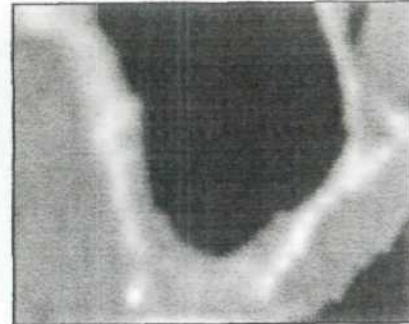
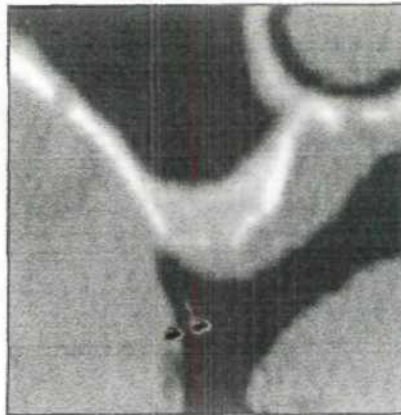


Fig 3 Intraoperative photograph of the bony window prepared in the lateral sinus wall during a sinus floor augmentation. Note a discernible intraosseous anastomosis.

Fig 4 Postoperative CT scan of the case in Fig 3 after successful dissection of the intraosseous artery.

MATERIALS AND METHODS

Fifty CT scans from an available 625 patients (5% of available scans) undergoing sinus augmentation procedures at the New York University Department of Implant Dentistry were chosen at random for evaluation in this study. The scans were subjected to computerized analysis (SIM/Plant, Materialise/Columbia Scientific, Glenburnie, MD) for location and measurement. If the endosseous branch of the posterior superior alveolar artery was observed in the lateral wall, measurements were taken to record the distance from the lower border of the artery to the alveolar crest (using a caliper rule calibrated to 0.5 mm) (Fig 1). The mean values and standard deviations of the measuring results were calculated.

RESULTS

The intraosseous branch of the artery was radiographically discernible in 51.4% of scans on the right side and

in 54.3% of scans on the left side, for an overall average of 52.9%. The average distance of the artery from the alveolar crest was 16.0 mm (± 3.5 mm) on the right side and 16.7 mm (± 3.0 mm) on the left side, for an average of 16.4 mm (± 3.5 mm). Of the arteries located, 80% were more than 15 mm from the crest, and 20% were 15 mm or less from the alveolar crest (Figs 1 to 4).

DISCUSSION

The progressive atrophy of the alveolar ridge with age and tooth loss results in changes in the blood supply to that area. The maxilla is very densely vascularized in young, dentate individuals. In older, edentulous populations, the number of vessels and vessel diameter decreases, while tortuosity of the vessels increases.^{9,10}

Solar and associates⁸ reported on a human cadaver study of the blood supply to the lateral wall of the maxillary sinus. It was shown to derive from 2 branches of the maxillary artery, the infraorbital

artery and the posterior superior alveolar artery. These arteries anastomose, forming both an extraosseous loop near the periosteum and an intraosseous loop in the lateral wall of the sinus. The intraosseous loop was found in 100% of the anatomic specimens, and its location was an average of 18.9 mm (\pm 2.82 mm) from the alveolar crest. The extraosseous loop was found in only 44.4% of the anatomic specimens; its location was an average of 22.75 mm (\pm 1.49 mm) from the alveolar crest. In the present radiographic study, the artery was observed in the CT scans in only 52.9% of the cases. The average distance from the artery to the alveolar crest was 16.4 mm; thus, there was good agreement between the present study and that of Solar and associates.

Two factors are of clinical significance in regard to surgical therapy. With the present current methods of presurgical evaluation (CT scan), it was possible to identify the location of the intraosseous vessel in only 53% of the cases. The artery can sometimes be seen visually, after a full-thickness mucoperiosteal flap is elevated, but usually only in the cases with larger arteries, which will typically be seen on the CT scan. The second factor is related to the position of the osteotomy. If the goal is to place implants of 13 to 15 mm in length, the superior osteotomy cut will be made approximately 15 mm from the alveolar crest and the inferior cut will be made approximately 2 to 3 mm from the floor of the sinus. The mesial and distal cuts (those that would sever the artery) connect the superior and inferior cuts. In the present study, according to the CT scan data, 80% of the arteries were located more than 15 mm from the crest. In Solar's study, the artery was located slightly higher than in the present study. This indicates that only approximately 20% of the cases present a potential surgical complication.

Intraoperative bleeding from a compromised vessel in the lateral wall is not threatening because of the small size of the artery. It can make visualization of the schneiderian membrane difficult, thus making membrane elevation more difficult, and it can interfere with placement of the graft material. This bleeding can usually be controlled by pressure with a moist gauze pad.

If the operator is concerned about possible compromise to the vessel, the incidence can be reduced by performing an elevated osteotomy in which the window is not made to full height but the membrane is elevated internally.⁷ It may also be possible to utilize a crestal sinus elevation technique.

Solar and coworkers also demonstrated the presence of an extraosseous vascular anastomosis in 44%

of their anatomic specimens. As this anastomosis is located in the area of the periosteum overlying the lateral wall at a higher level than the intraosseous anastomosis, it fell outside the scope of this radiographic study. Soft tissue bleeding complications, rather than the previously discussed bony bleeding, can occur if this extraosseous vessel is compromised. As the exposure of the lateral wall is made with a full-thickness mucoperiosteal flap, the vascular compromise would be the result of an inappropriate anterior releasing incision.

There are 2 additional considerations of importance in determining the potential for intraoperative complications related to compromise of this vessel in the lateral wall. The first is that in cases where the alveolar ridge has been severely resorbed, there is the likelihood that the vessel will be closer to the crest than the reported average value of 16.4 mm. Secondly, one would expect this vessel to be less of a risk for a bleeding complication in older patients, as the vessel would be of reduced diameter.

This vessel, though radiographically evident only 53% of the time, is present 100% of the time. This is but one of the reasons that careful soft tissue handling and a knowledge of anatomy as it relates to sinus membrane elevation and primary wound closure are critical in the prevention of intraoperative complications.^{11,12}

CONCLUSIONS

From the findings of this study, the following conclusions can be drawn:

- The intraosseous artery could be visualized in CT scans in 52.9% of this series of cases.
- The average height of the artery from the alveolar crest was 16.4 mm.
- Because of its location, the intraosseous artery has the potential to cause bleeding complications in approximately 20% of normally positioned lateral window osteotomies.

This information can be used to alter the surgical approach in order to avoid potential intraoperative complications.

ACKNOWLEDGMENTS

The authors acknowledge the contribution of Drs Geon Kim and Adolfo Magalhaes.

REFERENCES

1. Jensen OT, Shulman LB, Block MS, Iacono VJ. Report of the Sinus Consensus Conference of 1996. *Int J Oral Maxillofac Implants* 1998;13(suppl):11-45.
2. Tong DC, Rioux K, Drangsholt M, Beirne OR. A review of survival rates for implants placed in grafted maxillary sinuses using meta-analysis. *Int J Oral Maxillofac Implants* 1998;13:175-182.
3. Boyne PJ, James RA. Grafting of the maxillary sinus floor with autogenous marrow and bone. *J Oral Surg* 1980;38:613-616.
4. Summers RB. The osteotome technique: Part 3: Less invasive methods of elevating the sinus floor. *Compendium Cont Educ Dent* 1994;15:698-708.
5. Fugazzotto PA. Sinus floor augmentation at the time of maxillary molar extraction: Technique and report of preliminary results. *Int J Oral Maxillofac Implants* 1999;14:536-542 [erratum 1999;14:902].
6. Wood RM, Moore DL. Grafting of the maxillary sinus with intraorally harvested autogenous bone prior to implant placement. *Int J Oral Maxillofac Implants* 1988;3:209-214.
7. Smiler DG. The sinus lift graft: Basic technique and variations. *Pract Periodont Aesthet Dent* 1997;9:885-893.
8. Solar P, Geyerhofer U, Traxler H, Windish A, Ulm C, Watzek G. Blood supply to the maxillary sinus relevant to sinus elevation procedures. *Clin Oral Implants Res* 1999;10:34-44.
9. Watzek G, Ulm C, Solar P, Matejka M. Surgical criteria for endosseous implant placement. *Pract Periodont Aesthet Dent* 1993;5:87-94.
10. Ulm C, Solar P, Gsellman B, Matejka M, Watzek G. The edentulous maxillary alveolar process in the region of the maxillary sinus—A study of physical dimension. *Int J Oral Maxillofac Surg* 1995;24:279-282.
11. van den Bergh JP, ten Bruggenkate CM, Disch FJ, Tuinzing DB. Anatomic aspects of sinus floor elevations. *Clin Oral Implants Res* 2000;11:256-265.
12. Chanavaz M. Sinus graft procedures and implant dentistry: A review of 21 years of surgical experience (1979-2000). *Implant Dent* 2000;9:197-206.