

70

Special reprint from

20<sup>TH</sup>  
ANNIVERSARY

Volume 20 Number 1 2005

# JOMI

The International Journal of  
**ORAL & MAXILLOFACIAL IMPLANTS**

## **Histologic Evaluation of Bone-Implant Contact of Immediately Loaded Transitional Implants After 6 to 27 months**

Stuart J. Froum, DDS/Harel Simon, DMD/Sang-Choon Cho, DDS/  
Nicholas Elian, DDS/Michael D. Rohrer, DDS, MS/Dennis P. Tarnow, DDS

OFFICIAL JOURNAL OF THE ACADEMY OF OSSEointegration

# Histologic Evaluation of Bone-Implant Contact of Immediately Loaded Transitional Implants After 6 to 27 months

Stuart J. Froum, DDS<sup>1</sup>/Harel Simon, DMD<sup>2</sup>/Sang-Choon Cho, DDS<sup>3</sup>/  
Nicholas Elian, DDS<sup>4</sup>/Michael D. Rohrer, DDS, MS<sup>5</sup>/Dennis P. Tarnow, DDS<sup>6</sup>

**Purpose:** Transitional implants (TIs) were developed as a method of providing fixed provisional restorations for the implant patient who wishes to avoid removable temporary restorations during implant healing. Success of TIs depends on achieving sufficient osseointegrated bone-to-implant contact (BIC) during the provisional prosthesis phase. To date, little data are available on the degree of BIC of these implants in function. The purpose of this study was to histologically evaluate the BIC of TIs following various periods of loading. **Materials and Methods:** Histologic analysis of 33 immediately loaded implants from 21 patients was performed. All TIs had turned machined surfaces and were made of commercially pure titanium (grade 1). These transitional implants were in function for an average of 10.8 months (range: 6 to 27 months). Before the definitive restoration was provided, all of the TIs were removed with trephine drills and sent for hard tissue histomorphometric analysis. **Results:** The average percentage of BIC was  $52.9\% \pm 13.81\%$  (range 25.1% to 83%). **Discussion:** Although TIs are traditionally removed when the definitive implants are restored, the BIC and clinical integration of the TIs in the present study may suggest a change in TI protocol. Studies are indicated to examine long-term use of TIs as sole support or in conjunction with definitive implants in definitive implant-supported restorations. **Conclusion:** The percentage of BIC achieved with TIs was similar to that documented in the literature for conventional turned, machine-surfaced implants. *INT J ORAL MAXILLOFAC IMPLANTS* 2005;20:54-60

**Key words:** bone-to-implant contact, immediate loading, implant surfaces, transitional implants

<sup>1</sup>Clinical Professor, Department of Periodontics and Department of Implant Dentistry, New York University Krieser Dental Center, New York, New York.

<sup>2</sup>Clinical Assistant Professor, University of Southern California School of Dentistry, Los Angeles, California; Private Practice, Beverly Hills, California.

<sup>3</sup>Assistant Clinical Professor, and Research Scientist, Department of Implant Dentistry, New York University Krieser Dental Center, New York, New York.

<sup>4</sup>Assistant Professor and Director, Department of Implant Dentistry, New York University Krieser Dental Center, New York, New York.

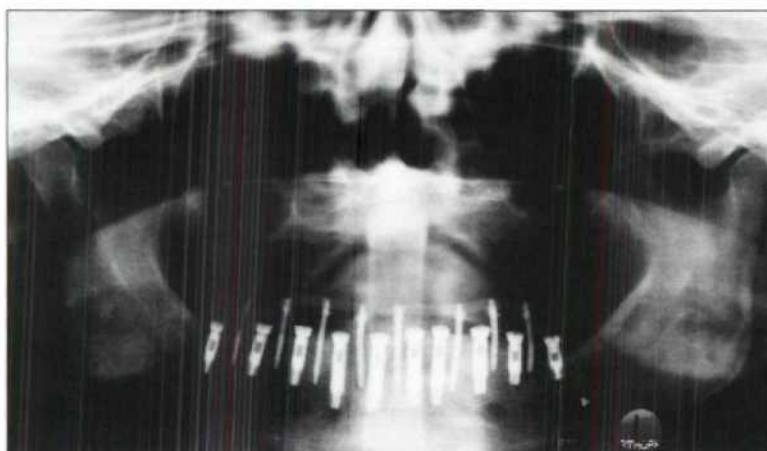
<sup>5</sup>Professor and Director, Division of Oral and Maxillofacial Pathology and Hard Tissue Research Laboratory, University of Minnesota School of Dentistry, Minneapolis, Minnesota.

<sup>6</sup>Professor and Chairman, Department of Implant Dentistry, New York University Krieser Dental Center, New York, New York.

**Correspondence to:** Dr Stuart J. Froum, Department of Periodontics and Department of Implant Dentistry, New York University Krieser Dental Center, 17 West 54th Street, New York, NY 10019. Fax: +212 246 7599. E-mail: dr.froum@verizon.net

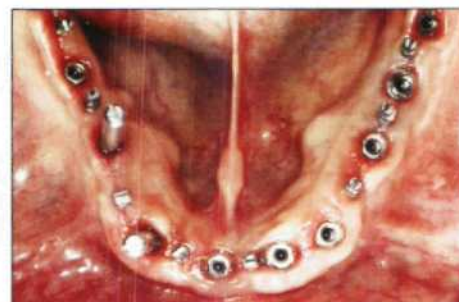Traditionally the protocol recommended to achieve osseointegration of endosseous implants required healing in the absence of functional loading for a period of 3 to 6 months.<sup>1</sup> This protocol produced a predictably high implant success rate.<sup>2</sup> However, to avoid transmucosal loading of the implants during the early healing period, patients were required to refrain from wearing any removable prostheses for at least 2 weeks after implant placement. The prostheses were then relined with a resilient liner every 3 weeks until placement of the definitive implant-supported restoration. Patients often objected to having to function without any temporary restoration and then to wearing a removable prosthesis while awaiting completion of the definitive restoration. As a result, some patients were reluctant to pursue the recommended implant therapy.

Several methods were suggested to avoid the use of a removable provisional prosthesis: a serial extraction technique, immediate loading of implants, and



**Fig 1a** (Left) Radiograph of TIs supporting a fixed provisional prosthesis while the restorative implants are healing without loading.

**Fig 1b** (Below) The TIs and restorative implants.



the use of transitional implants (TIs) to support a fixed provisional prosthesis. The serial extraction technique is a method in which strategically located hopeless teeth are temporarily retained across the arch to support fixed provisional prostheses during implant healing.<sup>3</sup> This method avoids transmucosal loading of the implants and allows the patient to function with a fixed provisional prosthesis during the time of implant healing and restoration. However, a second surgical phase, additional extractions, and implant placement are required following the initial implant healing and loading. This "serial approach" adds a minimum of 6 months to 1 year to the treatment time prior to the seating of the definitive restoration. The additional treatment time often results in loosening of the remaining abutment teeth, and also increases the risk of loosening and fracture of the provisional prostheses. This, in turn, increases the time and the cost of the entire treatment.<sup>3</sup>

Several investigations have tested the immediate loading of implants as a method of avoiding the use of removable provisional prostheses during implant restoration. This technique reduces the number of surgical procedures and shortens treatment time. However, the protocol suggested requires the use of at least 4 or 5 implants at least 10 mm or longer, which are splinted with cross-arch stabilization.<sup>4-6</sup> Possible failure of implants placed into immediate function is a potential disadvantage and must be considered in treatment planning utilizing immediate loading.

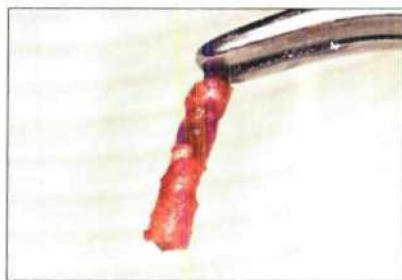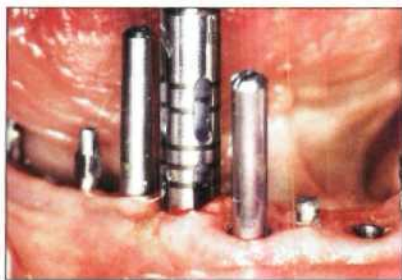TIs were developed as a method of providing fixed provisional restorations for the implant patient who wishes to avoid any removable temporary restorations during implant healing. A fixed provisional prosthesis supported by TIs can provide the patient with improved esthetics and function during the osseointegration period. Moreover, osseointegration can proceed without transmucosal loading.<sup>7</sup> A

fixed provisional prosthesis supported by TIs also allows areas of bone augmentation (ie, potential implant sites) to heal uneventfully.<sup>8</sup> They facilitate accurate implant placement with improved stability of the surgical template and enhanced visibility of the surgical sites.<sup>9</sup> There are 4 transitional implant systems available: the Immediate Provisional Implant (IPI; Nobel Biocare USA, Yorba Linda, CA), the Modular Transitional Implant (MTI; Dentatus USA, New York, NY), the Mini Dental Implant (MDI; Imtec, Ardmore, OK), and the Temporary Implant (Bicon, Boston, MA). Although the manufacturer's instructions vary for each system, the foremost advantage of any TI system is the delivery of a stable temporary fixed prosthesis prior to and at the time of implant placement.

Success of TIs depends on achieving sufficient osseointegrated bone-to-implant contact (BIC) during the provisional prosthesis phase. To date, there is a paucity of data available on the degree of BIC of TIs in function. The purpose of the present study was to histologically evaluate the bone-to-implant contact of transitional implants in function for various time periods.

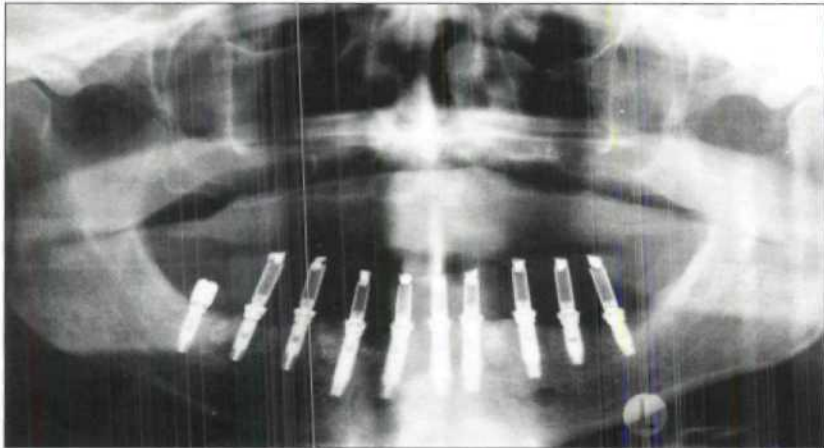
## MATERIALS AND METHODS

Histologic analysis was performed on 27 TIs from 17 patients who received treatment at New York University Department of Implant Dentistry and 6 TIs from 4 patients from who received treatment at the School of Dentistry, University of California at Los Angeles. Seventeen of the 33 TIs were placed in the mandible and 16 in maxilla. All 33 TIs were designated as test TIs prior to being removed by trephine. Prior to TI placement all patients signed an informed consent describing the placement and removal of the TIs. The TIs were all manufactured by the same company (Dentatus USA) and were made of commercially pure



**Fig 2a** (Left) Removal of a TI with a trephine.

**Fig 2b** (Right) TI and bone core removed and submitted for processing.



**Fig 2c** Radiograph following removal of the TIs. The restorative implants now support the fixed provisional prosthesis.

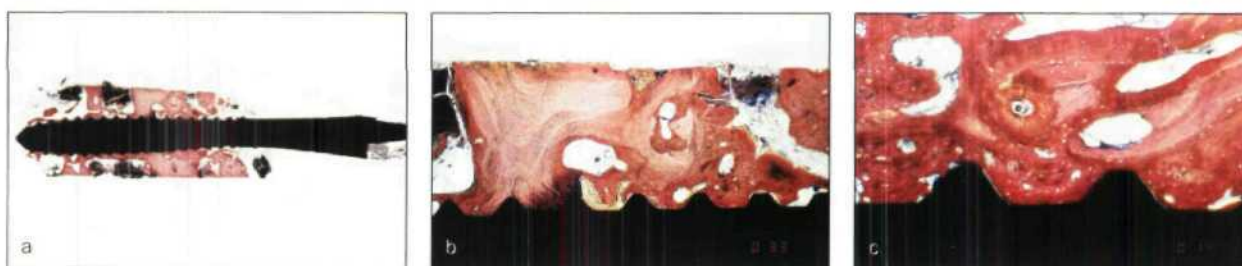
titanium (cpTi; grade 1) with turned surfaces. All TIs were placed according to the manufacturer's instructions and were placed in locations that did not interfere with permanent implant placement. These positions were also selected so as to ensure that trephine removal of the TIs would not compromise any permanent implant (Fig 1). All TIs were splinted and were used to support acrylic resin provisional restorations that were fabricated chairside or processed by a dental laboratory.

The TIs were immediately loaded and functioned for 6 to 27 months. None of the 33 test TIs had to be removed prematurely, and all were nonmobile at the time of removal. Before the definitive restorations were seated, all 33 transitional implants were removed with trephine drills (Fig 2). In most cases, the prosthetic portion of the implant was removed with a high-speed bur prior to use of the trephine (Ace Surgical Supply, Brockton, MA).

The specimens were sent to the Hard Tissue Research Laboratory at the University of Minnesota (or to the University of Oklahoma before the laboratory was moved) for processing and evaluation in 10% neutral buffered formalin. All implant cores were sectioned in half buccolingually and immediately dehydrated with a graded series of alcohols for 9 days. Following dehydration, the specimens were infiltrated with a light-curing embedding resin (Technovit 7200 VLC, Kulzer, Wehrheim, Germany). Following 20 days of infiltration with constant shaking at

normal atmospheric pressure, the specimens were embedded and polymerized by 450-nm light. The temperature of the specimens never exceeded 40°C. The specimens were then prepared by the cutting/grinding method of Donath.<sup>10,11</sup> The specimens were cut to a thickness of 150  $\mu\text{m}$  on an EXAKT cutting/grinding system (EXAKT Apparatebau, Norderstedt, Germany). Following this, the specimens were polished to a thickness of 35  $\mu\text{m}$  using the EXAKT microgrinding system followed by alumina polishing paste. This thickness is optimal for the preservation of titanium on the microscope slide and high-power microscopic observation of undecalcified bone and soft tissue.

The slides were stained with Stevenel's blue and Van Gieson's picric fuchsin. Histomorphometric measurements of digitized images were completed using a Macintosh G4 computer (Cupertino, CA) and a combination of Adobe PhotoShop (San Jose, CA) and the public domain NIH Image program (developed at the U.S. National Institutes of Health and available on the Internet at <http://rsb.info.nih.gov/nih-image>). The total length of bone in contact with the implant was measured, and the percentage of the threaded portion of the implant in contact with bone was calculated. Calculations were also made of the bone marrow and the connective tissue in contact with the threaded portion of the TI coronal to the first point of bone contact (Fig 3).



**Figs 3a to 3c** Photomicrograph of the TI and surrounding bone (Stevenel's blue and Van Gieson's picric fuchsin; original magnification  $\times 2$ ). The TI functioned for 8.5 months in the mandibular right second molar area of the patient in Fig 1 (Stevenel's blue and Van Gieson's picric fuchsin; original magnification  $\times 2$  for *b* and  $\times 4$  for *c*).

## RESULTS

The location (maxilla or mandible), loading period (months), and percentage of BIC of the 33 transitional implants in this study are listed in Table 1. The average percentage of BIC was  $52.9\% \pm 13.81\%$  with a range from 25.1% to 87.3%. The average time of loading was 10.8 months (range, 6 to 27 months). The average percentage of BIC of the 17 mandibular TIs was  $54.61\% \pm 12.74\%$  (range, 27.5% to 77.9%). The average percentage of BIC of the 16 maxillary TIs was  $51.09\% \pm 15.07\%$  (range, 25.1% to 87.3%). Figure 4 shows the distribution of the percentage of BIC of the TIs in this study.

## DISCUSSION

Clinical<sup>4,12</sup> as well as histologic evidence<sup>13-15</sup> of osseointegration has been demonstrated with non-submerged, immediately loaded implants. Based on previous reports, splinting, with primary stabilization of individual immediately loaded implants, was recommended to keep implant micromovement below a critical level and allow osseointegration.<sup>16</sup> Albrektsson and Jacobsson<sup>17</sup> reported that the bone-to-implant interfacial reaction was not determined by factors relating to the implant alone. They stated that parameters such as surgical technique and loading conditions were equally important for reliable osseointegration.

Zubery and associates<sup>18</sup> published a histomorphometric study of TIs placed in dogs. They placed 3 TIs into each side of the mandible in 3 dogs. Anterior and posterior implants were loaded immediately, while the middle implants remained unloaded. After 11 or 12 weeks, histologic examination showed that the mean BIC of the 7 loaded implants was 46.1% and that of the 3 unloaded implants was 54.0%. Simon and Caputo<sup>19</sup> evaluated removal torque of immediately loaded transitional endosseous implants in humans. They suggested that stronger

**Table 1** Location, Loading Period, and % Bone-to-Implant Contact of the Transitional Implants

Location/ patient	Loading period (mo)	% BIC
Mandible		
AI	6	44.0
	6	51.0
	6	51.0
CW	10	67.6
FS	7	34.2
HP	8	48.0
	8	51.0
	8	57.0
	8	67.0
IA	6	53.0
MS	9	27.5
RC	12	64.5
RD	15	53.6
SA	10	66.8
	10	77.9
SD	12	64.8
WA	13	49.4
Maxilla		
BO	6	45.0
BS	8	44.8
CK	27	73.7
	27	87.3
EF	12	45.6
IB	14	41.9
JF	12	52.1
	12	56.5
KW	8	39.4
	8	60.3
LF	14	25.1
OP	7	61.0
PL	12	58.2
SD	12	41.4
	12	48.9
WA	13	36.3
Average	10.8	52.9 $\pm$ 18.81

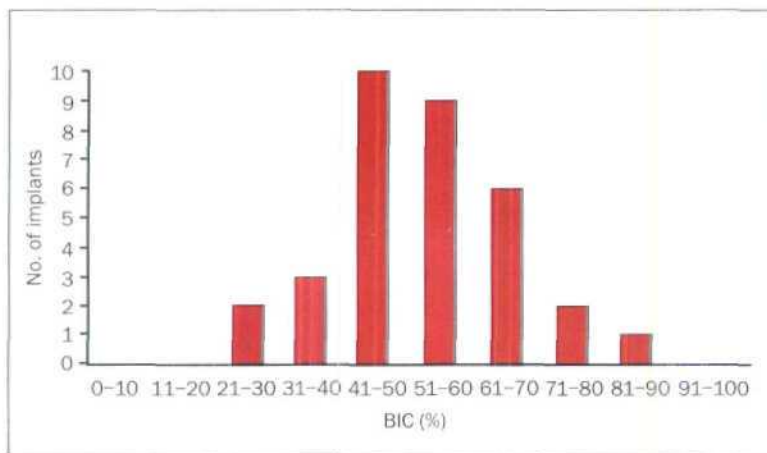


Fig 4 Distribution of BIC for all TIs removed.

integration was observed in the mandible compared to the maxilla, and removal torque levels of these implants indicated varying degrees of integration.

The results of the present study show similar percentages of BIC regardless of whether the TIs were placed in the maxilla or mandible. This may be a function of the location and the type of native bone present in the areas in which the TIs were placed. Proussaefs<sup>20</sup> reported that histologic evaluation of a single immediately loaded TI in the mandibular arch of a 52-year-old woman that was in function for 18 months revealed 81.3% BIC. He suggested that immediately loaded TIs could potentially achieve and maintain a high degree of osseointegration for a longer period of time than that currently expected (3 to 6 months).

Steflik and colleagues<sup>21</sup> compared 120 implants from 6 different implant systems placed in 30 dog mandibles. Their results indicated no significant difference between loaded and unloaded titanium root-form screw-type implants. The range of the percentage of BIC for a 1-stage titanium implant was 50.1% to 59.6%. Lazzara et al<sup>22</sup> compared the percentage of BIC for acid-etched implants and turned, machined cpTi implants. They placed 2- × 5-mm, threaded titanium implants that were acid-etched on one side and machined on the opposite side in the posterior maxillae of 11 patients. Histologic analysis of the unloaded implants was done after 6 months. The mean BIC value for the acid-etched surfaces was 72.96%, and that for the turned, machined surfaces was 33.98%.

Weinlaender and coworkers<sup>23</sup> compared the percentage of BIC of 3 types of endosseous dental implants. The implants placed in the edentulous mandibles of 7 adult mongrel dogs had 3 different surfaces (A = titanium, B = titanium plasma-sprayed, C = hydroxyapatite (HA) -coated). Twenty-one implants were harvested after 12 weeks. Their study

showed that the percentage of contact was 45.66% for A, 54.99% for B, and 71.35% for C. Gottlander and Albrektsson<sup>24</sup> compared plasma-sprayed HA-coated titanium implants with an uncoated control in a short-term (6 weeks) and a longer-term (1 year) study. They placed threaded HA-coated implants and uncoated cpTi screw implants in the rabbit tibial metaphysis. After either 6 weeks or 1 year postplacement, the loaded implants were histomorphometrically analyzed. Six weeks after implant placement, the average direct bony contact was 65% for the HA-coated implants and 53% for the cpTi implants. After 1 year, the average percentage of BIC contact was 59% for the HA-coated screws and 74% for the cpTi screws.

Conner and colleagues<sup>25</sup> conducted a histomorphometric study to assess the BIC of 3 different rough-surfaced implants following guided bone regeneration in manmade defects in a canine model. Following a healing period of 6 months, they compared the BIC in the regenerated and non-regenerated areas for TPS, acid-etched, and HA implants. The mean percentage of BIC was 25.08% in regenerated bone and 16.96% in non-regenerated bone with TPS implants; 16.24% in regenerated bone and 28.78% in non-regenerated bone with acid-etched implants; and 48.25% in regenerated bone and 25.60% in non-regenerated bone with HA-coated implants.

In the present study, the average percentage of BIC of the TIs was 52.9% ± 13.81%, with a range of 25.1% to 87.3%. Ideally, comparisons should be made of implants placed in identical tooth locations where the quality of the native bone is similar. This was not possible in the current human study, in which implants were placed where they were clinically required to support fixed provisional prostheses. TIs are usually placed in interproximal sites so as not to interfere with the definitive implants. For example, an implant might be placed between the positions of

teeth 5(14) and 6(13). Thus, even if 2 patients both received implants in the "maxillary right canine position," the implants might in fact be in dissimilar positions because of their interproximal and buccal or lingual positions. Even with a total of 33 TIs from 21 patients, finding enough similar sites to use implants placed at corresponding locations as a biologic unit would be difficult and would have yielded a very small sample size. Therefore, the range of BIC presented in the current study, 25.1% to 87.3%, may reflect differences in location and type of native bone present at the site of TI placement.

However, these results are consistent with the values obtained for BIC of restorative implants as documented in the aforementioned studies. In 1 clinical study, immediate loading of implants restored with fixed prostheses in completely edentulous mandibles in 27 patients was reported with a 99% success rate at the time of final evaluation for restorative fabrication.<sup>26</sup> Another clinical study evaluated 5-year results of 9 of 10 patients who received definitive implants that were immediately loaded in the edentulous mandible.<sup>27</sup> Results showed a 97% survival rate of implants immediately loaded with acrylic resin prostheses that were not disturbed for 3 months. The prosthesis survival rate was 100%. These studies documented successful immediate loading of restorative implants. However, TIs are traditionally removed when the restorative implants are restored. The BIC and clinical integration of the TIs noted in the present study may suggest a change in TI protocol. Long-term studies are necessary to determine if these implants require removal or can function alone or with permanent implants in the definitive restoration.

## CONCLUSION

The average percentage of BIC of TIs followed for 6 to 27 months in this study population was 52.9%, which is similar to that reported in the literature for turned, machine-surfaced implants.

## ACKNOWLEDGMENTS

The authors thank Dr Young S. Cho, resident in the Department of Implant Dentistry at New York University Krieser Dental Center for his work on this article and Dr Khaled Bohsali for contributing his histologic data. The authors would also like to extend their appreciation to Drs Deborah Bradley, Earl Freymiller, Alan Felsenfeld, Tara Aghaloo, and Sascha Jovanovic, UCLA School of Dentistry, for their surgical support, and Mr Hari Prasad, BS, MDT, of the University of Minnesota for the undecalcified histology and the histomorphometric measurements.

## REFERENCES

1. Brånemark P-I. Osseointegration and its experimental background. *J Prosthet Dent* 1983;50:399-410.
2. Albrektsson T, Dahl E, Enbom L, et al. Osseointegrated oral implants: A Swedish multicenter study of 8,139 consecutively inserted Nobelpharma implants. *J Periodontol* 1988;59:287-296.
3. Balshi TJ. Converting patients with periodontally hopeless teeth to osseointegration prostheses. *Int J Periodontics Restorative Dent* 1988;8:8-33.
4. Tarnow DP, Emtiaz S, Classi A. Immediate loading of threaded implants at stage 1 surgery in edentulous arches: Ten consecutive case reports with 1- to 5-year data. *Int J Oral Maxillofac Implants* 1997;12:319-324.
5. Salama H, Rose LE, Salama M, Betts N. Immediate loading of bilaterally splinted titanium root-form implants in fixed prosthodontics—A technique reexamined: Two case reports. *Int J Periodontics Restorative Dent* 1995;15:345-361.
6. Schnitman PA, Wöhrle PS, Rubenstein JE, DaSilva JD, Wang NH. Ten-year results for Brånemark implants immediately loaded with fixed prostheses at implant placement. *Int J Oral Maxillofac Implants* 1997;12:495-503.
7. Froum SJ, Emtiaz S, Bloom M, Scolnick J, Tarnow D. The use of transitional implants for immediate fixed temporary prostheses in cases of implant restorations. *Pract Periodontics Aesthet Dent* 1998;10:737-746.
8. Petrangaro P. Fixed temporization and bone augmented ridge stabilization with transitional implants. *Pract Periodontics Aesthet Dent* 1997;9:1071-1078.
9. Simon H. Use of transitional implants to support a surgical guide: Enhancing the accuracy of implant placement. *J Prosthet Dent* 2002;87:229-232.
10. Rohrer MD, Schubert CC. The cutting-grinding technique for histological preparation of undecalcified bone and bone-anchored implants: Improvement in instrumentation and procedures. *Oral Surg Oral Med Oral Pathol* 1992;74:73-78.
11. Donath K, Breuner G. A method for the study of undecalcified bones and teeth with attached soft tissues: Sawing and grinding technique. *J Oral Pathol* 1982;11:318-326.
12. Randow K, Ericson I, Nyber K, Peterson A, Glantz P-O. Immediate functional loading of Brånemark dental implants. An 18-month study. *Clin Oral Implants Res* 1999;10:8-15.
13. Lum LB, Beirne OR, Curtis DA. Histologic evaluation of HA-coated versus uncoated titanium blade implants in delayed and immediately loaded applications. *Int J Oral Maxillofac Implants* 1991;6:456-462.
14. Sagara M, Akagawa Y, Nikai H, Tsuru H. The effects of early occlusal loading on one-stage titanium alloy implants in beagle dogs: A pilot study. *J Prosthet Dent* 1993;69:281-288.
15. Piattelli A, Corigliano M, Scarano A, Costigliola G, Paolantonio M. Immediate loading of titanium plasma-sprayed screw-shaped implants in man: A clinical and histological report of 2 cases. *J Periodontol* 1997;68:591-597.
16. Chiapasco M, Gatti C, Rossi E, Haefliger W, Markwalder TH. Implant-retained mandibular overdentures with immediate loading: A retrospective multicenter study on 226 consecutive cases. *Clin Oral Implants Res* 1997;8:48-57.
17. Albrektsson T, Jacobsson M. Bone-metal interface in osseointegration. *J Prosthet Dent* 1987;57:597-607.
18. Zubery Y, Bichacho N, Moses O, Tal H. Immediate loading of modul transitional implants: A histologic and histomorphometric study in dogs. *Int J Periodontics Restorative Dent* 1999;19:343-353.

19. Simon H, Caputo AA. Removal torque of immediately loaded transitional endosseous implants in human subjects. *Int J Oral Maxillofac Implants* 2002;17:839–845.
20. Proussaefs P. Histologic evaluation of an immediately loaded titanium provisional implant retrieved after functioning for 18 months: A clinical report. *J Prosthet Dent* 2003;89:331–334.
21. Steflik DE, Lake FT, Sisk AL, et al. A comparative investigation in dogs: 2-year morphometric results of the dental implant-bone interface. *Int J Oral Maxillofac Implants* 1996;11:15–25.
22. Lazzara RJ, Testori T, Trisi P, Porter S, Weinstein RL. A human histologic analysis of Osseotite and machined surfaces using implants with 2 opposing surfaces. *Int J Periodontics Restorative Dent* 1999;19:117–129.
23. Weinlaender M, Kenney EB, Lekovic V, Beumer J III, Moy PK, Lewis S. Histomorphometry of bone apposition around three types of endosseous dental implants. *Int J Oral Maxillofac Implants* 1992;7:491–496.
24. Gottlander M, Albrektsson T. Histomorphometric studies of HA-coated and uncoated CP titanium threaded implants in bone. *Int J Oral Maxillofac Implants* 1991;6:399–404.
25. Conner KA, Sabatini R, Mealey BL, Takacs VJ, Mills MP, Cochran DL. Guided bone regeneration around titanium plasma-sprayed, acid-etched, and hydroxyapatite-coated implants in the canine model. *J Periodontol* 2003;74:658–668.
26. Ganeles J, Tosenberg MM, Holt RL, Reichman LH. Immediate loading of implants with fixed restorations in the complete edentulous mandible: Report of 27 patients from a private practice. *Int J Oral Maxillofac Implants* 2001;16:418–426.
27. Wolfinger GJ, Balshi TJ, Rangert B. Immediate functional loading of Brånemark System implants in edentulous mandibles: Clinical report of the results of developmental and simplified protocols. *Int J Oral Maxillofac Implants* 2003;18:250–257.