

THE USE OF TRANSITIONAL IMPLANTS FOR IMMEDIATE FIXED TEMPORARY PROSTHESES IN CASES OF IMPLANT RESTORATIONS

Stuart Froum, DDS*
 Shahram Emthiaz, DDS†
 Mitchell J. Bloom, DDS‡
 Jeffery Scolnick, DDS§
 Dennis P. Tarnow, DDS||

10
6
AUGUST FROUM

While the original Brånemark implant protocol has continued to evolve, the avoidance of implant loading during osseointegration remains a prerequisite with all implant systems. Immediately loaded transitional implants have recently been developed to support the fabrication of a fixed provisional prosthesis that provides implant patients with improved aesthetics and function during the osseointegration period. In this manner, osseointegration can occur free from prosthetic and transmucosal loads. This article describes the use of transitional implants and presents a classification of three different case types.

The high success rate of osseointegrated implants has been well documented.^{1,4} Although the original Brånemark protocol has been modified, the prerequisite of avoiding any loading during the healing phase of

osseointegration continues to be the accepted regimen with all implant systems. A recent multicenter study that utilized a two-stage implant in a one-stage procedure (nonsubmerged placement) accomplished this without loading until the implants osseointegrated.⁵ Protocols for immediate implant placement into fresh extraction sockets also avoid loading of the implant until completion of a 4- to 6-month healing phase.⁶⁻¹⁰

In order to avoid directing occlusal forces on the newly placed implant, tooth-supported fixed or removable provisional restorations are recommended. If this is not possible due to lack of supporting teeth, the implant patient may not receive a provisional prosthesis, or may be asked to refrain from wearing the denture for several weeks. When the denture is worn, it must be relieved and relined to provide a cushion over the implant site.

*Clinical Professor, Department of Periodontics, Ashman Department of Implant Dentistry, New York University College of Dentistry, New York, New York.

†Clinical Associate Professor; Director, International Implant Program, Ashman Department of Implant Dentistry, New York University College of Dentistry, New York, New York.

‡Clinical Assistant Professor, Department of Periodontics, Department of Comprehensive Care and Applied Practice Administration and Behavioral Sciences, Ashman Department of Implant Dentistry, New York University College of Dentistry, New York, New York.

§Resident, Implant Fellowship Program, Ashman Department of Implant Dentistry, New York University College of Dentistry, New York, New York.

||Professor and Chairman, Ashman Department of Implant Dentistry, New York University College of Dentistry, New York, New York.

Stuart Froum, DDS
 The Rockefeller Apartments, Ste. 1C/D
 17 West 54th Street
 New York, NY 10019

Tel: 212-586-4209
 Fax: 212-246-7599

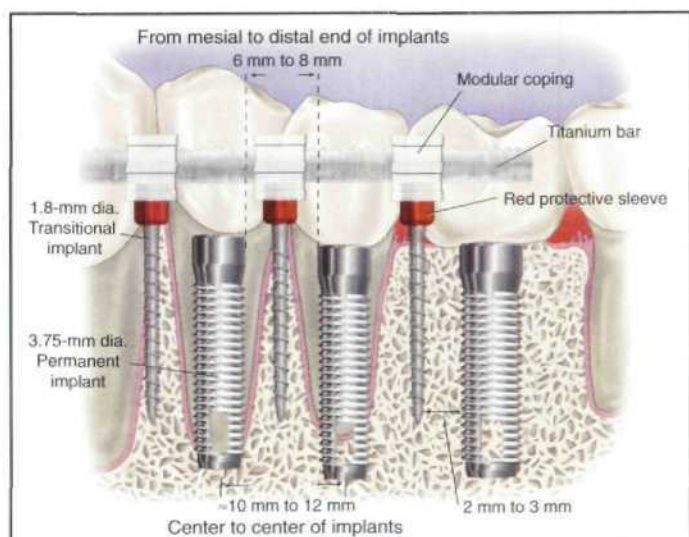


Figure 1. Diagram of the partially edentulous mandible demonstrates placement of transitional implants in relation to conventional implants. Note the space requirements between the implant fixtures.

Despite adjustments to the denture, transmucosal loading may occur during the bone healing phase due to remodeling of the soft and hard tissue under the removable partial or complete denture. Furthermore, the patient may object to wearing a removable prosthesis while awaiting the completion of the definitive implant-supported restoration.

A method of avoiding removable provisional prostheses utilizes a "serial" extraction technique, where hopeless teeth are strategically retained across the arch to support a fixed provisional prosthesis during implant healing.¹¹ Following the 4- to 6-month healing period, the first implants are loaded, the hopeless teeth extracted, and additional implants inserted. This method, while resulting in a more comfortable healing phase, requires a second surgical phase following the initial implant healing and loading that adds a minimum of 6 months to 1 year prior to the delivery of the definitive prosthesis.

Several studies have avoided the use of removable transitional prostheses by the immediate loading of osseointegrated implants.¹²⁻¹⁸ While this technique may be indicated in select fully edentulous patients, this modality will require additional long-term statistical data to assess the indications, contraindications, and rate of success.

The concept of immediately loaded transitional implants has recently been introduced.^{19,20} Following placement of the permanent implants, this procedure provides an implant patient with a fixed temporary prosthesis prior to and/or during the immediate postoperative healing phase. During this time, osseointegration can occur

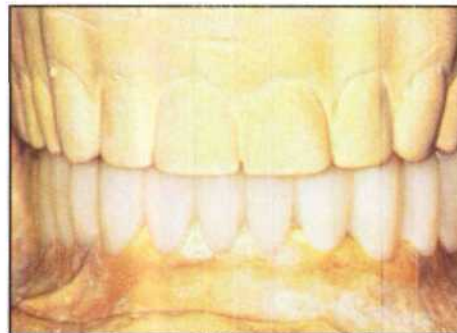

Figure 3. Waxup on the articulator. Note the anticipated alignment of the restoration.

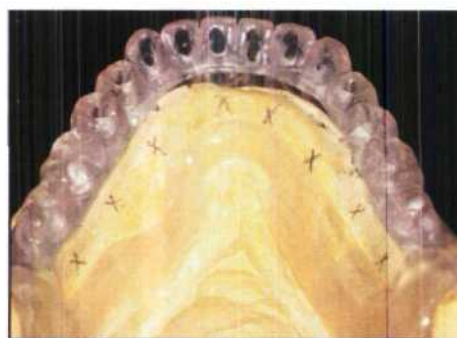


Figure 4. Lingual view of the surgical template fabricated from the waxup.

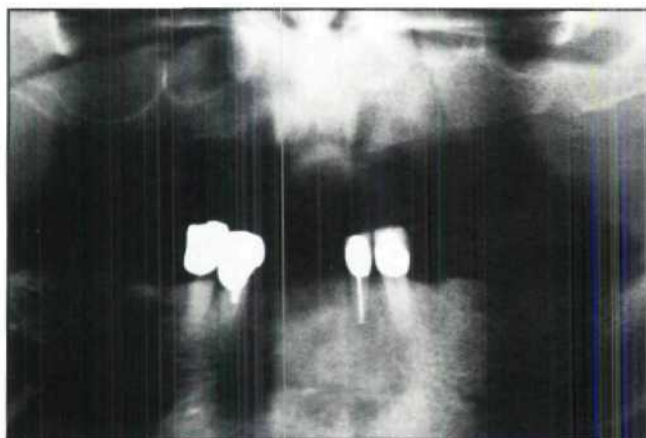


Figure 2. Panoramic radiograph for case type 1. Remaining teeth #21, #22, #27, and #28 were diagnosed as hopeless and extracted.

free from prosthetic and transmucosal loads. Titanium transitional implants (TIs) (MTI MP, Dentatus USA, New York, NY) are 1.8 mm in diameter and are placed into edentulous sites to serve as fixed abutments for provisional prostheses. These TIs are placed into sites adjacent to or between the permanent implant sites so as not to interfere with healing when the implants are placed. The TIs are removed once the permanent implants are ready to be loaded and can support a fixed temporary prosthesis (4 to 6 months postplacement). This article describes the use of the TIs and presents a classification of the different case types. Histological data will be presented in a subsequent paper to describe the healing response to these implants at the time of removal.

Presurgical Planning Phase

Prior to implant placement and extraction of any hopeless teeth that may be present, irreversible hydrocolloid (Jeltrate, Dentsply/Caulk, Milford, DE) impressions of the maxillary and mandibular arches are made and poured in die stone. These diagnostic casts are mounted in centric

1000 rpm) used with twist drills in permanent implant placement. The TIs are subsequently inserted at low speed (25 rpm to 30 rpm) with a right-angle handpiece and driver. They may also be placed and manually adjusted with a rotated winged key. The apicocoronal position of the TIs can also be adjusted with the winged key following suturing of the flap to allow placement of the prefabricated prosthetic components. Although the TIs may be bent to improve parallelism, excessive bending should be avoided to prevent mobility of the TI or fracture of the TI head. Following insertion of the TIs, the slotted implant heads should be aligned to conform to the ridge arch form by rotating the implant clockwise or counterclockwise with the manual winged key. In the rare case when multiple permanent implant placement does not allow space for the TIs, a TI may be placed in an implant site and, at a future appointment when the other implants are integrated, removed and immediately replaced by a permanent implant. As with the "serial" extraction technique, this will provide the patient with a fixed temporary prosthesis through the entire healing period, but will extend the treatment by 6 to 12 months prior to the completion of the definitive prosthesis.

Materials and Methods

To date, 78 transitional implants have been placed by the authors in 15 patients and restored with fixed provisional prostheses. Following loading of the permanent implants, 14 TIs in 6 of the 15 patients were removed with a trephine bur to examine the healing of the bone surrounding these implants.

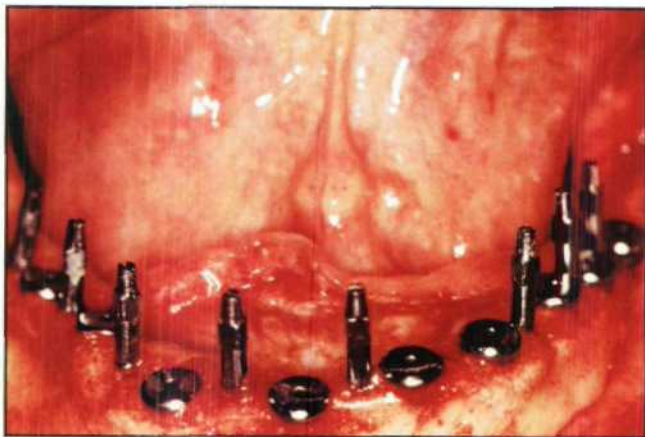

Figure 8. Ten TIs were placed between the implants. Note the spacing between each fixture.

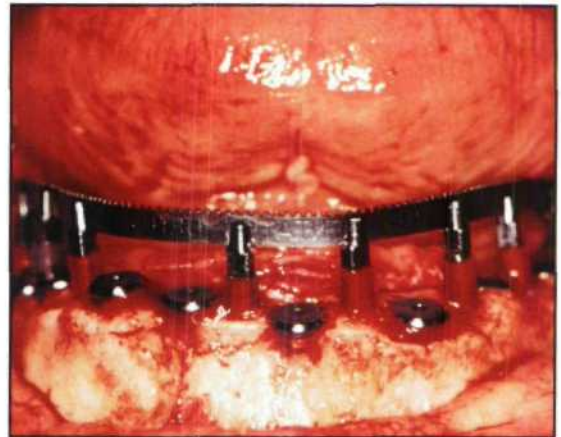


Figure 9. A prefabricated titanium bar was bent to conform to the arch shape of the TIs and fitted into the slot at the top of the TIs. Note red plastic protective spacers on TIs.

Classification

Type I

Fully or partially edentulous healed ridge. Placement of implants and TIs simultaneously with immediate fabrication and delivery of a fixed provisional prosthesis at Stage I surgery.

Type II

Hopeless teeth extracted and concurrent placement of TIs and delivery of fixed temporary prosthesis. Following healing of the extraction sockets, implants are placed.

Type III

Hopeless teeth extracted; implants, TIs and fixed provisional prosthesis are placed simultaneously (Stage I surgery).

Case Presentations

Type I

A 76-year-old male patient presented with a maxillary denture and four remaining mandibular teeth. Although the patient was in good systemic health, the remaining teeth (#21, #22, #27, and #28) were diagnosed as nonrestorable due to extensive recurrent caries and bone loss (Figure 2). Complete maxillary and mandibular dentures were fabricated and delivered immediately following the extraction of the remaining teeth. Approximately 2 months postoperatively, following numerous visits for adjustments, the patient felt "insecure" about eating and speaking with the mandibular denture, and was referred to the authors for diagnosis and treatment. The patient

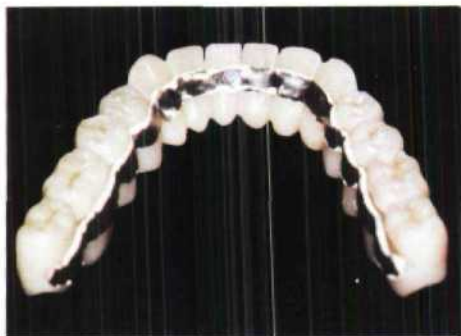

Figure 5. Laboratory-processed fixed prosthesis with lingual reinforced casting.

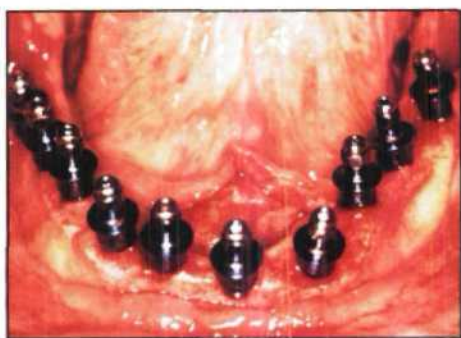

Figure 6. The permanent implants were placed in position #18 through #20, #22, #23, and #27 through #31.

relation by using an arbitrary facebow on a semiadjustable articulator, and a diagnostic waxup for a fixed temporary prosthesis is fabricated. This waxup is duplicated twice, first to fabricate a custom surgical template from clear autopolymerizing resin, and second to fabricate a laboratory-processed fixed provisional prosthesis. Alternately, an acrylic shell and a vacuform may be prepared for the chairside fabrication of an immediate provisional restoration with the prefabricated components during the initial surgical visit. The provisional heat-processed acrylic resin prosthesis has a lingual casting fabricated of semiprecious metal, which provides reinforcement, rigidity, and cross-arch bracing.^{21,22}

The radiographic template is marked with gutta-percha in the central fossae, extending vertically over the buccal and lingual aspects of each tooth. The patient is instructed to wear the radiographic template when the computed axial tomography (CAT) scan is performed. The CAT scan and template are utilized to identify potential implant and TI sites. The locations for the implants and TIs are marked on the diagnostic cast, ensuring that the

implants are 6 mm to 8 mm apart from the distal margin of one implant to the mesial margin of the adjacent implant (Figure 1). This distance allows placement of the TI with a minimum of 2 mm to 3 mm between each TI and the adjacent implant. The TIs do not have to emerge where the final tooth is to be positioned, but function to support the fixed provisional prosthesis while the permanent implants are healing. It is important, however, to place as many TIs as possible across the arch, thus creating a wide anterior-posterior distribution to support the provisional prosthesis for the duration of the healing period.

Surgical Planning Phase and Armamentarium

Following flap reflection and implant insertion, the TIs are placed. Transitional implants are manufactured from extruded tempered commercially pure titanium metal. They are available in lengths of 14 mm, 17 mm, and 21 mm. The corresponding endosseous threaded portions of the implants are 7 mm, 10 mm, and 14 mm in length. All implants have a common 3-mm supracrestal unthreaded section and a prosthetic abutment square-slotted head. This leaves a 7-mm prosthetic head remaining supracrestally. The transitional implants and their metal components must be autoclaved prior to use.

When the location of the TIs is determined, a single drill (1.3 mm in diameter) is used to prepare the osteotomy site. A depth-marking sleeve is placed on the drill shank at 7 mm, 10 mm, or 14 mm from the drill tip to serve as a depth guide. The osteotomies are prepared under copious irrigation; the drill rotates at the same speed (approximately

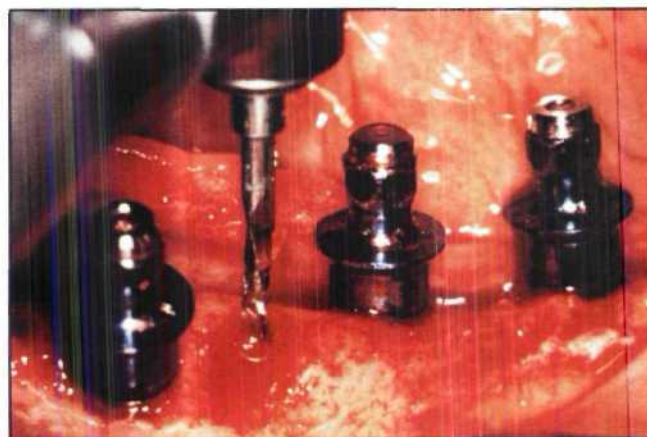


Figure 7. Osteotomy for the placement of TIs between the permanent implants leaves a minimum of 2 mm to 3 mm between implants and TIs.

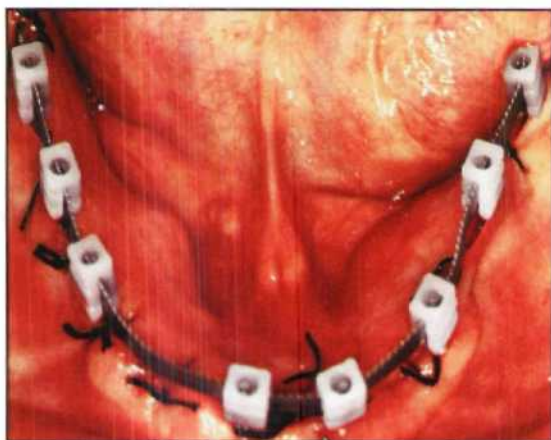


Figure 10. A white modular coping abutment was fitted onto each TI. The fixed provisional restoration will be seated on these copings.

was satisfied with the function of the complete maxillary denture, but would not wear the mandibular denture and desired implants. In an attempt to deliver a fixed provisional prosthesis as soon as possible, transitional and permanent implants were planned for insertion simultaneously.

Prior to surgery, a surgical template and temporary prosthesis were fabricated from the waxup as described previously (Figures 3 through 5). The decision was made to utilize 3.75-mm diameter implants. The implant sites were marked on the diagnostic cast, allowing a minimum distance of 10 mm to 12 mm center to center from each implant, to ensure that each implant would emerge at a site conducive to restoration. This distance allowed 2 mm to 3 mm between each of the TIs (\varnothing 1.8 mm) and the adjacent implants. Following the examination of the CAT scan, implants and 10 TIs were selected for placement.

Crestal incisions were made from mandibular right to left third molar regions. Vertical incisions were made in the third molar areas to aid in reflection of the flap. Following flap reflection, the surgical stent was placed. Using this surgical template, 10 implants (Osteotite, 3i, Palm Beach Gardens, FL) were placed in the following areas: #18 through #20, #22, #23, #25, #27, #29, #30 and #31, followed by placement of 10 TIs (Figures 6 through 8). After placement of the cover screws, plastic protective spacers were placed on the TIs. A prefabricated titanium bar was bent to conform to the arch shape of the TIs and fitted into the slots atop the TIs (Figure 9). The flap was subsequently closed with resorbable sutures.

A white modular coping abutment was then fitted onto each TI (Figure 10) and luted with acrylic resin to the metal bar.

The fixed provisional prosthesis was relined with acrylic over the metal bar, the abutments, and the TIs (Figure 11). Once the acrylic had set, the margins were trimmed and polished, the occlusion was adjusted, and the prosthesis was cemented with carboxylate cement (Durelon, ESPE America, Norristown, PA) (Figure 12). This cement was used to avoid loosening of the prosthesis, which might compromise the osseointegration of the TIs by macromovement.^{23,26} Macromovement of the provisional prosthesis could also result in fibrous encapsulation of the TIs, impingement of the prosthesis on the mucosa surrounding the permanent implants, or cause cross-contamination from mobile TIs.

The second surgical procedure was performed 4 months postoperatively (Figure 13). Following flap reflection and prior to placement of the healing abutments, the implants were tested for mobility (Periotest, Siemens Dental, Bensheim, Germany).²⁷ All implants tested -4 to -2 . An impression was then made of all 10 permanent implants and TIs. The provisional prosthesis was resealed on the TIs. The impression of the implants was poured and mounted against the opposing cast. Temporary cylinders were placed down to the hex of the laboratory analogs and trimmed to the appropriate vertical dimension. At the following appointment, the cylinders were placed on the 10 permanent implants. The provisional prosthesis was then hollowed out over the cylinders, relined, and retained with

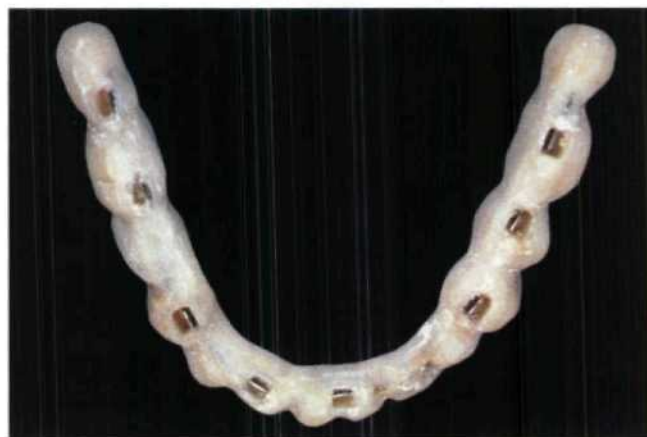

Figure 11. The metal bar and the white modular coping will adhere within the prosthesis, which has been relined with acrylic material.

screws over the permanent implants. Four of the TIs were trephined out to obtain cores for histological examination of surrounding bone, and six were removed by counter-clockwise rotation with the winged socket key (Figure 14).

Type II

A 64-year-old female patient with an unremarkable medical history presented for treatment of a "loose" mandibular anterior fixed partial denture. The patient had undergone a lifetime of extensive dental treatment that included numerous extractions, periodontal surgery, fixed ceramometal prostheses, and removable partial dentures. The patient had received maintenance care on a regular basis. Clinical and radiographic evaluation revealed generalized severe bone loss, recurrent caries, and Class I or II mobility of all remaining teeth, with the exception of tooth #21 (Figure 15). The prognosis for the remaining teeth was hopeless. Since the patient refused to wear any type of removable prosthesis, the final treatment plan included fabrication of maxillary and mandibular full-arch fixed ceramometal implant-supported prostheses. The patient also desired to avoid wearing complete removable dentures as provisional prostheses. As a result of the amount of bone observed during the CAT scans, TIs were included in the treatment plan to support the fixed provisional prosthesis.

Surgical Phase

Preliminary impressions were made and casts were mounted for the fabrication of laboratory-processed metal-reinforced fixed provisional prostheses. The remaining mandibular teeth (#20, #22, #23, and #26 through #29) were surgically extracted with the exception of tooth #21, which was retained to support the prosthesis and was later extracted prior to completion of the case. In order to prevent the occupation of the sites required for the standard implants, which were indicated for placement 2 to 3 months postextraction, 4 TIs were placed in the interseptal bone (Figure 16). To improve parallelism, the TIs were slightly bent with the paralleling instrument. While verifying the vertical dimension of occlusion, the provisional prosthesis was relined with self-curing acrylic resin and seated on the TIs. The flaps were secured with silk in an interrupted vertical mattress fashion to allow for suture removal without necessitating the removal of the provisional prosthesis for access.

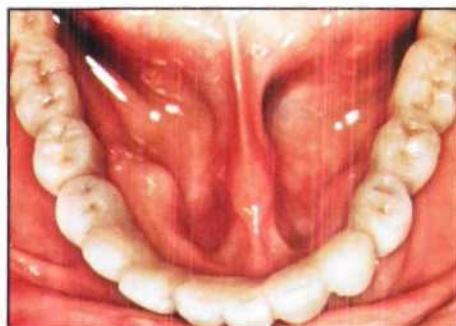

Figure 12. The fixed provisional prosthesis is cemented with carboxylate cement.

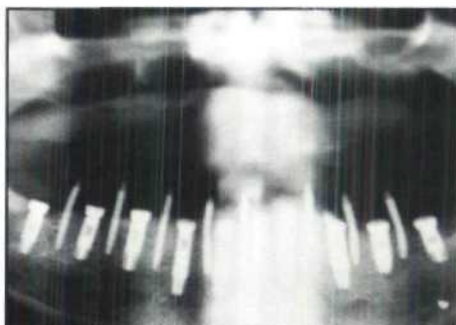


Figure 13. Panoramic film taken prior to the initiation of Stage II surgery.

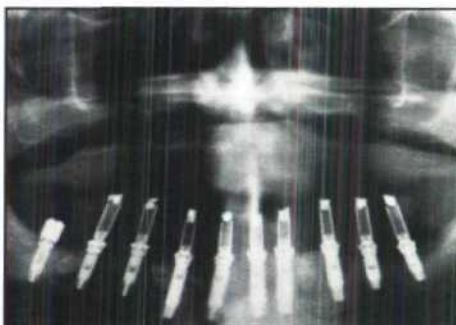


Figure 14. Panoramic radiograph following the delivery of the new fixed provisional prosthesis. All TIs have been removed.

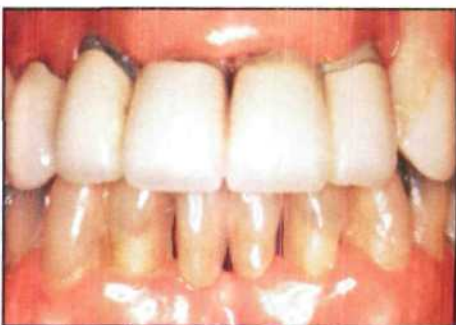

Figure 15. Preoperative facial view of a 64-year-old patient who presented for treatment of a "loose" mandibular anterior fixed partial denture.

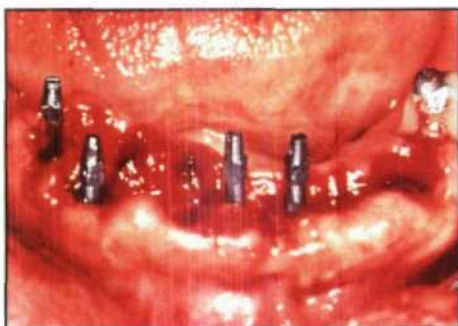

Figure 16. Four TIs were placed in the mandible 2 to 3 months postextraction. Tooth #21 was retained to support the prosthesis.

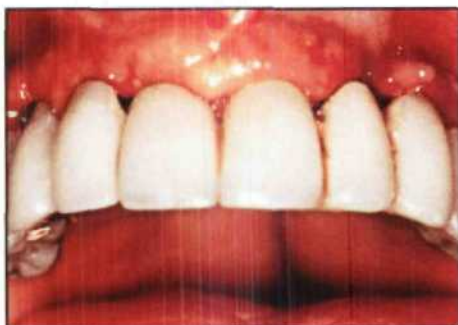

Figure 17. Facial view of the provisional prosthesis 1 week following delivery.

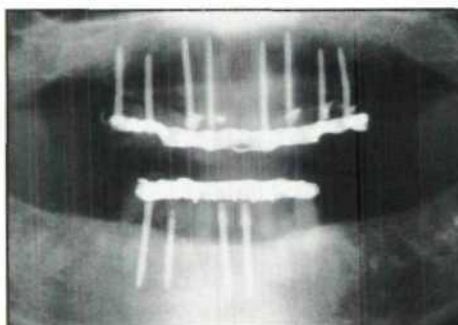


Figure 18. Panoramic radiograph of the maxillary and mandibular TIs.

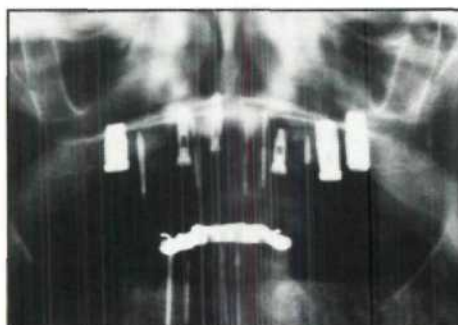


Figure 19. Panoramic radiograph following placement of maxillary implants. At this stage, the implants were submerged to permit healing.

At a subsequent visit, the aforementioned protocol was repeated for the maxillary arch, although no natural teeth were retained. Once the teeth (#6 through #13) were extracted, the TIs were placed in interseptal bone and the fixed provisional prosthesis was placed and cemented (Figure 17). One week postoperatively, the patient was reappointed for suture removal and verification of the occlusal scheme. The provisional prostheses were stable and the patient received maintenance instruction. Three months following the placement of the maxillary TIs, six implants (Osteotite, 3i, Palm Beach Gardens, FL) were inserted in the following areas: #3, #6, #8, #11, #14, and #15 and subsequently submerged to permit healing (Figures 18 and 19). Six months following initial placement, the five remaining TIs were removed and three additional implants were placed at sites #4, #9, and #12 and submerged to allow for healing (Figure 20).

Type III

A 76-year-old female patient presented with the chief complaint of a mobile lower anterior fixed partial denture. The fixed prosthesis extended from tooth #22 to tooth #28 and utilized #22, #23, #27, #28 as abutments. The opposing dentition of the patient consisted of natural teeth from tooth #2 to tooth #13, with a fixed prosthesis from tooth #2 to tooth #4 (Figure 21).

Following a clinical examination and review of several treatment options, the treatment plan was presented and included an implant-supported mandibular prosthesis. The patient desired to avoid wearing any removable prosthesis. It was therefore decided to incorporate TIs at the time of Stage I surgery to provide the patient with a fixed metal-reinforced provisional prosthesis. Appropriate records and impressions were made to allow for fabrication of the fixed provisional prosthesis to be utilized at Stage I. At the patient's second appointment, all remaining mandibular teeth were extracted and implants were placed (Figure 22). Seven implants (ITI Bonelit, Straumann, Cambridge, MA) were placed into the areas of teeth #20, #21, #24, #26 and #27 through #29; eight TIs were also placed (Figure 23). Once suturing was performed, the fixed provisional prosthesis was hollowed out to create access for alignment with the TIs. Plastic protective spacers were placed on the TIs to prevent the acrylic from locking onto the heads of the TIs. The prosthesis was

aligned over the TIs and the pontic areas were relieved to establish a pressure-free zone to avoid transmucosal loading. This also permitted access for suture removal without having to remove the fixed prosthesis. The temporary prosthesis was cemented with carboxylate cement. The sutures were removed 1 week postoperatively, and healing was uneventful (Figure 24).

Five months postoperatively, Stage II surgery was performed, and biopsy cores were harvested from TIs located at #18, #24, and #31 positions. The remaining TIs were removed using a manual winged key. All implants were tested for stability and recorded -4 to -1 scores. The provisional prosthesis was hollowed out, and 7 titanium cylinders were screwed into position. The provisional cylinders were cut to the vertical dimension of occlusion as indicated by the patient. The provisional prosthesis was relined with self-curing acrylic resin over the cylinders. Three weeks later, the final impression was made to fabricate the permanent fixed implant-borne prosthesis.

Results

Of the 78 TIs placed, 6 were lost in 3 patients. In one patient, 3 TIs loosened and were extracted when the provisional prosthesis was removed 2 weeks postinsertion. In the other patients, the loosening of 1 and 2 TIs required removal 3 and 4 weeks postinsertion, respectively. This did not affect the retention of the fixed provisional prostheses, which continued to function until second-stage abutment insertion surgery. In the patient where 3 TIs and

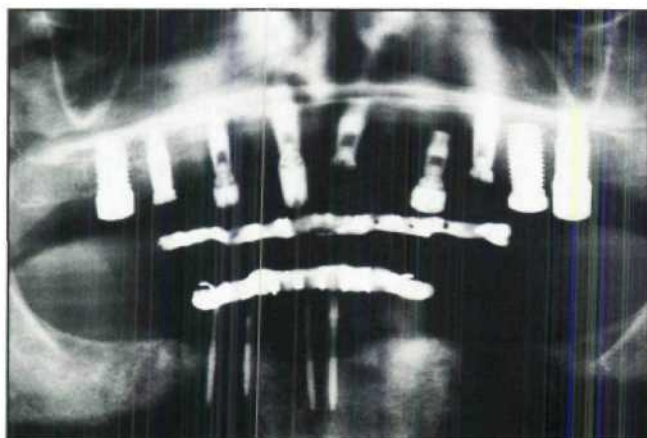


Figure 20. Panoramic radiograph demonstrates the initial placement of implants supporting the fixed splints. All TIs were removed and additional implants were placed.

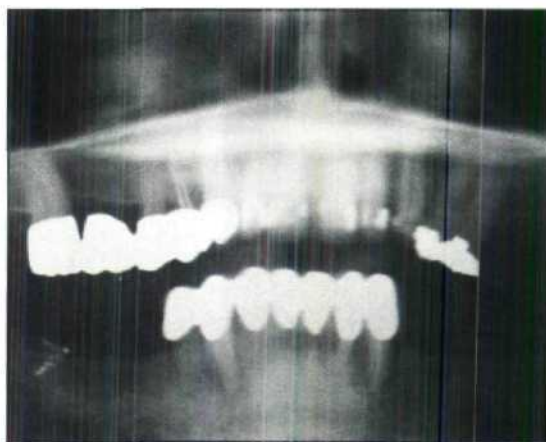


Figure 21. Preoperative panoramic radiograph of a Type III patient. All of the mandibular teeth were hopeless.

the fixed provisional prosthesis were removed, the patient wore her original complete denture for 1 week (which was relieved internally). Three additional TIs were subsequently placed and the fixed prosthesis was relined chairside.

In the patients where one, two, or three of the TIs were removed prematurely due to loosening, the fixed provisional prostheses were repeatedly removed 1, 2, and 3 weeks following insertion to remove sutures and examine and photograph the TIs. Of the 72 TIs that successfully supported the prostheses until loading of the implants, 7 were found to be mobile at the time of TI removal. They remained asymptomatic, however, and were able to function as transitional abutments for the fixed restoration during the implant healing phase. To date, none of the 15 patients experienced the loss of any permanent implant.

Discussion

The use of transitional implants to support fixed provisional prostheses has been documented in 15 consecutively treated implant patients. Five different implant systems were utilized in these 15 patients, and no implant failure has occurred to date. Although the exact benefit to implant survival (no transmucosal loading during healing) of utilizing these fixed temporary prostheses cannot be determined in this preliminary study, every patient reported increased comfort and satisfaction with fixed rather than removable provisional prostheses. Since the fixed transitional prosthesis that is placed on the TIs is fabricated from the prosthetic waxup (with teeth in the ideal position),

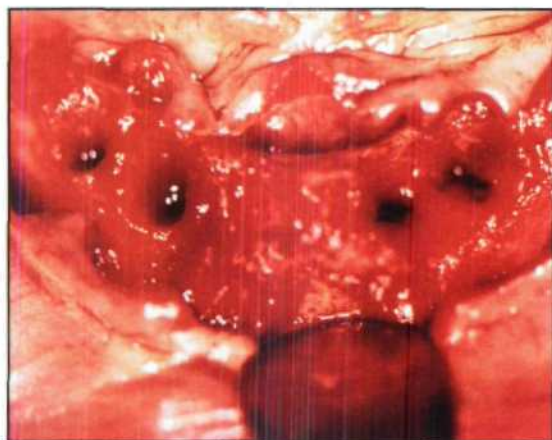


Figure 22. The patient's remaining teeth were extracted to facilitate implantation.

tissue contours related to crown, pontic position, and shape can be visualized and altered as necessary during implant healing. The transitional prosthesis can be used to modify tissue form by altering pontic design and contact point position so that the soft tissue/crown relationship in the definitive prosthesis has an improved aesthetic appearance.

It should be noted when treatment planning for cases including serial extractions, immediate loading of implants at Stage I, or transitional implants, the waxup that is performed initially must be modified. It has to be wider buccolingually, not only to provide clearance for the metal lingual casting, but also for the purpose of accommodating the bulky and large prosthetic components that are fitted onto either the permanent implants or the TIs. If the waxup is not modified to provide sufficient space, further hollowing may result in fracture of the prosthesis at a vital point of treatment.

It should also be noted that the prefabricated titanium bar that fits through the slots of the TI implant heads is flexible. Although it provides interconnected vertical support and some rigidity to the temporary prostheses, it is advantageous to incorporate a lingual cast metal framework for added stability and longevity of the prosthesis. When utilizing the TI system in the maxillary arch, careful attention must be given to ensure parallelism of the TIs. This is facilitated by the use of the surgical template. Although bending of the TIs with the instrument provided can also aid in parallelism, excessive bending may cause mobility, fracture, and possible failure of the TIs. Lack of

parallelism creates the need for relining and removal of the provisional prosthesis. If this occurs, removal and replacement of the nonaligned TI is indicated. The prosthesis can then be relined chairside with self-curing acrylic resin, reinserted, and cemented. The use of a carboxylate cement is recommended to avoid loosening of the fixed prosthesis until abutment placement 4 to 6 months postsurgery. In the initial cases, loss of 6 TIs in 3 patients was caused in large part by the removal and recementation of the provisional prostheses or by failure to use a suitable cement, which resulted in loosening of the prosthesis. In more recent cases, the use of resorbable sutures did not require the removal of the prostheses, and none of the TIs had to be removed prematurely. In circumstances where silk sutures are desired, it is recommended that sutures and the prosthesis be trimmed to allow suture removal without necessitating removing the prosthesis. Following suture placement and prior to cementation of the fixed provisional prosthesis, the clinician must ensure that the sutures have a clear path of removal.

The importance of not removing the temporary prosthesis during implant healing has been discussed previously.^{17,22,26} Moreover, the clinical findings of the authors regarding the importance of cross-arch stability with incorporating the lingual cast metal framework in the fixed provisional prosthesis are consistent with previously published material.^{17,21} In cases where arch form and site availability compromise the use of a lingual cast metal framework in the laboratory-processed fixed restoration, the use of a preformed vacuum-fit shell is indicated. This

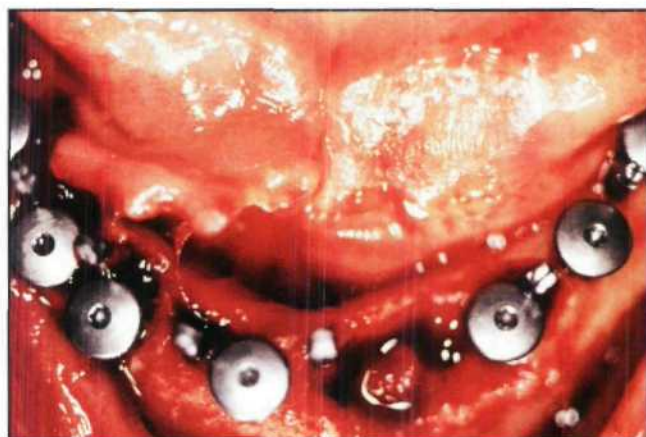

Figure 23. Occlusal view of the patient following the simultaneous placement of seven implants along with eight transitional implants.

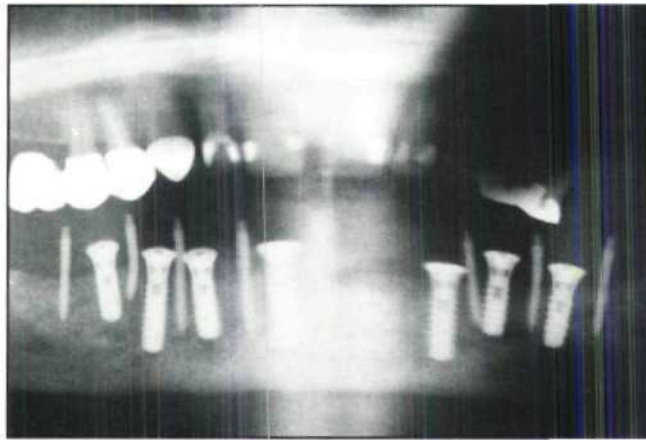


Figure 24. Panoramic radiograph indicates the placement of the permanent and transitional implants following the completion of Stage 1 surgery.

is fabricated from the waxed-up die stone cast and relined chairside with self-curing acrylic resin. In these cases, the prefabricated titanium bar must be incorporated in the fixed provisional prosthesis for alignment and rigidity. It is established in the acrylic resin during the relining of the vacuum acrylic shell over the TIs. All other aspects of placement and cementation are as described previously.

Conclusion

In each case presented, TIs were used to provide immediate fixed provisional prostheses and avoid premature implant loading. There are also advantages to using TIs in cases requiring ridge augmentation utilizing guided bone regeneration with barrier membranes, onlay block, inlay block, or particulate grafts, to avoid loading of the grafted area.²⁸

The use of TIs to provide the implant patient with a fixed temporary prosthesis during the implant healing phase has been documented. Presurgical planning, surgical technique, and provisional prosthetic fabrication have been described and classified according to three different case types. Histological documentation and the definitive prosthetic restorations will be presented in subsequent papers.

Acknowledgment

The authors mention their gratitude to Seung-Il Eom, DDS, Waascok Min, DDS, Daniel Samaniego, DDS, and Urs Zellweger, DDS for their clinical assistance and Leonard Marotta, MDT, for technical and laboratory support.

References

1. Adell R, Lekholm U, Rockler B, Brånemark PI. A 15-year study of osseointegrated implants in the treatment of the edentulous jaw. *Int J Oral Surg* 1981;10(6):387-416.
2. Brånemark PI, Hansson BO, Adell R, et al. Osseointegrated implants in the treatment of the edentulous jaw: Experience from a 10-year period. *Scand J Plast Reconstr Surg Hand Surg* 1977;2(suppl 16):1-132.
3. Brånemark PI. Osseointegration and its experimental background. *J Prosthet Dent* 1983;50(3):399-410.
4. Zarb GA, Schmitt A. Osseointegration and the edentulous predicament: The 10-year-old Toronto study. *Brit Dent J* 1991;170(12):439-444.
5. Becker W, Becker BE, Israelson H, et al. One-step surgical placement of Brånemark implants: A prospective multicenter clinical study. *Int J Oral Maxillofac Impl* 1997;12(4):454-462.
6. Rosenquist B, Grenthe B. Immediate placement of implants into extraction sockets: Implant survival. *Int J Oral Maxillofac Impl* 1996;11(2):205-209.
7. Krump JL, Barnett BG. The immediate implant: A treatment alternative. *Int J Oral Maxillofac Impl* 1991;6(1):19-23.
8. Iozzara KJ. Immediate implant placement into extraction sites: Surgical and restorative advantages. *Int J Periodont Rest Dent* 1989;9(5):332-343.
9. Gelb DA. Immediate implant surgery: Three-year retrospective evaluation of 50 consecutive cases. *Int J Oral Maxillofac Impl* 1993;8(4):388-399.
10. Gomez RG, Schulte WV, Hoedt B, Axman KD. The Friolet-2 implant system: Five year clinical experience in single-tooth and immediately post extraction applications. *Int J Oral Maxillofac Impl* 1997;12(3):299-309.
11. Balshi JT. Converting patients with periodontally hopeless teeth to osseointegration prosthesis. *Int J Periodont Rest Dent* 1988;8(2):8-33.
12. Schnitman PA, Wohrle PS, Rubenstein JE. Immediate fixed interim prostheses supported by two-stage threaded implants: Methodology and results. *J Oral Implantol* 1990;16(2):96-105.
13. Linkow II, Donath K, Lemons JE. Retrieval analysis of a blade implant after 231 months of clinical function. *Implant Dent* 1992;1(1):37-43.
14. Schnitman PA. Brånemark implants loaded with fixed interim prostheses at fixture placement: Nine-year follow-up. *J Oral Implantol* 1995;21:235.
15. Sogara M, Akagawa Y, Nikai H, Tsumi H. The effects of early occlusal loading on one stage titanium alloy implants in beagle dogs: A pilot study. *J Prosthet Dent* 1993;69(3):281-288.
16. Salama H, Rose IF, Salama M, Belts NJ. Immediate loading of bilaterally splinted titanium root-form implants in fixed prosthodontics: A technique reexamined: Two case reports. *Int J Periodont Rest Dent* 1995;15(4):344-361.
17. Tamow DP, Emtiaz S, Classi A. Immediate loading of threaded implants at stage 1 surgery in edentulous arches: Ten consecutive case reports with 1 to 5 year data. *Int J Oral Maxillofac Impl* 1997;12(3):319-324.
18. Schnitman PA, Wohrle PS, Rubenstein JE, et al. Ten-year results for Brånemark implants immediately loaded with fixed prostheses at implant placement. *Int J Oral Maxillofac Impl* 1997;12(4):495-503.
19. Blatz MB, Hürzeler MB, Hildebrand D. Implant systems and their components. *Implantol* 1996;4:357-360.
20. Ravasini G, Ugalini G, Dalla TS, Ravasini E. Protocollo operativo per l'uso di impianti provvisori immediati (Mini Transitoriali Implants—MTI) *Dialog* 1996;1:43-47.
21. Emtiaz S, Tamow DP. Processed acrylic resin provisional with lingual cast metal framework. *J Prosthet Dent* 1998;79(4):484-488.
22. Goldman HM, Cohen DW. *Periodontal Therapy*, 6th ed. St Louis, MO: Mosby, 1980:1133-1135.
23. Brunski JB. Biomechanical factors affecting the bone-dental implant interface: Review paper. *Clin Mater* 1992;10:153-201.
24. Brunski JB. Avoid pitfalls of overloading and micromotion of intraosseous implants [interview]. *Dent Implantol Update* 1993;4(10):77-81.
25. Cameron H, Machab I, Pillar R. Porous surfaced titanium staples. *South Afr J Surg* 1972;10(2):63-70.
26. Cameron HU. The effect of movement on the bonding of porous metal to bone. *J Biomed Mater Res* 1973;7(4):301-311.
27. Schulte W, Lukas D. Periosteal to monitor osseointegration and to check occlusion in oral implantology. *J Oral Implantol* 1993;19(1):23-32.
28. Petrongaro PS. Fixed temporization and bone-augmented ridge stabilization with transitional implants. *Pract Periodont Aesthet Dent* 1997;9(9):1071-1078.

CONTINUING EDUCATION (CE) EXERCISE No. 23

To submit your CE Exercise answers, please use the answer sheet found within the CE Editorial Section of this issue and complete as follows: 1) Identify the article; 2) Place an X in the appropriate box for each question of each exercise; 3) Clip answer sheet from the page and mail it to the CE Department at Montage Media Corporation. For further instructions, please refer to the CE Editorial Section.

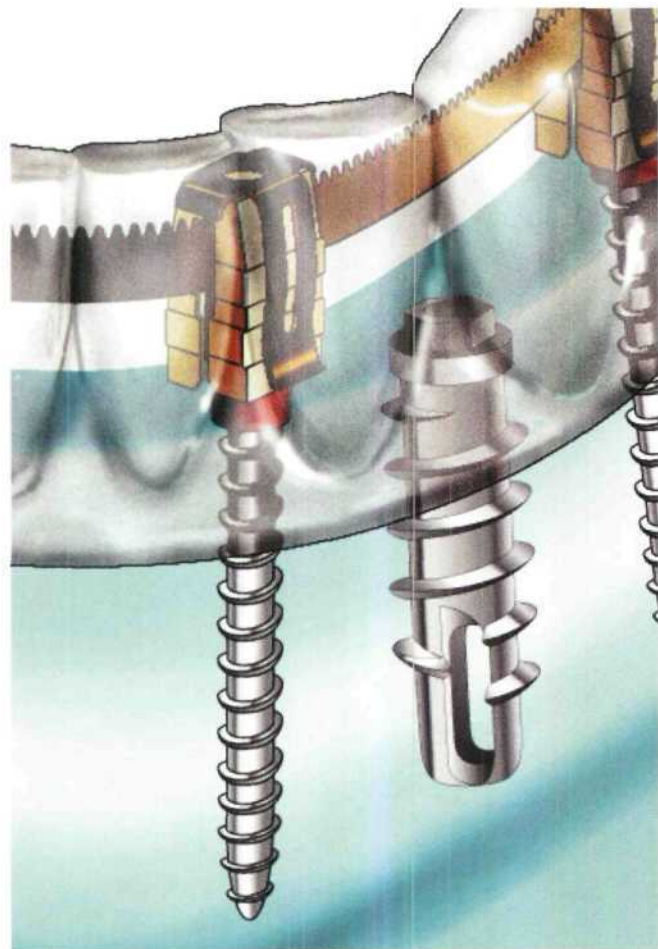
The 10 multiple-choice questions for this Continuing Education (CE) exercise are based on the article "The use of transitional implants for immediate fixed temporary prostheses in cases of implant restorations" by Stuart Froum, DDS, Shahram Emtiaz, DDS, Mitchell J. Bloom, DDS, Jeffery Scolnick, DDS, and Dennis P. Tarnow, DDS. This article is on Pages 737-746.

Learning Objectives:

This article describes the indications and technique for the use of transitional implants (TIs) and construction of an immediate fixed temporary prosthesis during implant healing. Case reports are described to illustrate the different case types and circumstances for the use of TIs. Upon reading and completion of this CE exercise the reader will have:

- An understanding of how and where transitional implants may be used in patients requiring implant prostheses.
- The ability to implement TIs in clinical procedures.

- 1. Indications for a transitional implant-supported fixed temporary prosthesis to avoid transmucosal loading include:**
 - a. Cases where there are not enough natural teeth remaining to support a fixed prosthesis.
 - b. Cases of ridge augmentation where a removable appliance would impinge on the healing ridge.
 - c. Cases of edentulous healed ridges where TIs are placed at the same time the permanent implants are inserted.
 - d. All of the above.
- 2. The minimum distance that must be present from distal margin of one implant to mesial margin of adjacent implant in order to place a TI between them is:**
 - a. 1 mm to 3 mm.
 - b. 3 mm to 4 mm.
 - c. 6 mm to 7 mm.
 - d. 9 mm to 10 mm.
- 3. A provisional heat-processed acrylic resin prosthesis with a lingual casting fabricated of semiprecious metal is recommended as the immediate fixed prosthesis over the TIs to provide:**
 - a. Rigidity.
 - b. Cross-arch bracing.
 - c. Reinforcement.
 - d. All of the above.
- 4. Although TIs are available in lengths of 14 mm to 21 mm, all implants have a supracrestal (nonthreaded) prosthetic head of:**
 - a. 3 mm.
 - b. 5 mm.
 - c. 7 mm.
 - d. 10 mm.
- 5. Transitional implants may be placed and adjusted manually with the:**
 - a. Bending instrument.
 - b. Rotated winged key.
 - c. Locking pliers.
 - d. Right-angle handpiece and driver.
- 6. Carboxylate cement is used to cement the temporary prosthesis over the TIs to avoid macromovement which may result in:**
 - a. Fibrous incapsulation of the TIs.
 - b. Impingement of the prosthesis on the mucosa around the permanent implants.
 - c. Cross-contamination from mobile TIs.
 - d. All of the above.
- 7. Resorbable sutures are recommended in conjunction with TI and immediate fixed provisional prosthesis use because:**
 - a. They are easier to place than silk.
 - b. The tissue may be more closely appositioned as compared to silk.
 - c. Clinicians are not required to remove the provisional prosthesis for suture removal.
 - d. All of the above.
- 8. The use of the prefabricated titanium bar that fits through the slots of the implant head in the provisional prosthesis provides:**
 - a. Rigidity.
 - b. Interconnected vertical support.
 - c. Retention.
 - d. a and b.
- 9. Excess bending of the TIs with the bending instrument is not recommended as it may cause the TIs to:**
 - a. Fracture.
 - b. Become mobile.
 - c. Fail.
 - d. All of the above.
- 10. The authors attribute premature loss of the TIs in the earlier cases to:**
 - a. Tapping off and/or recementation of the provisional prosthesis.
 - b. Poor insertion technique.
 - c. Placing the TIs too far apart.
 - d. Extremely wide buccolingual dimensions in the provisional prostheses.



Modular Transitional Implants

MTI-MP. Greatly appreciated by patients who can function the day after.

DENTISTS USING MTI GIVE THEIR PATIENTS WHAT THEY COME FOR —
CONFIDENCE, FUNCTION AND COMFORT.

- Dependable and economical anchoring supports for immediate restoration.
- Indispensable supports for failing key abutments and implant fixtures.
- Modular prosthetic components for the chairside construction of immediate restorations.
- The MTI pure Ti. 1.8mm implants are retrievable when they are no longer needed without perceptible bone loss or any patient discomfort.
- The patented MTI system is a great practice builder by helping you satisfy your patient's most urgent needs.

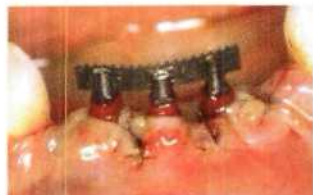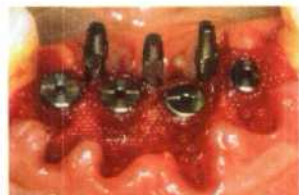
A sampling of your colleagues views:

"MTI is the Gold Standard of Implantology."
— K. Judy DDS, FICD, FACD

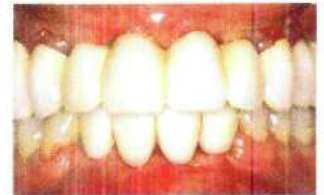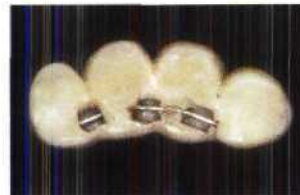
Now, with MTI System, "I am able to help a much larger percentage of patients to achieve their primary goal, the restoration of their dental health."
— C.H. Ganz DDS

"The MTI temporary implant plays a major role in providing high esthetic and implant dentistry. It is the answer to the prosthetic challenges of the past."
— D.T. Mayeda DDS

"Transitional Implants have been added to my lecture series and my challenge to my audience is: If you are not offering and performing this service, why not?"
— R.M. Pick DDS, MS



Photos courtesy Paul Petrungaro, DDS, MS, FICD, FACD.



MTI-MP, US Pat. #5,575,651 & Foreign Pat. pending

Dentatus USA, Ltd.
192 Lexington Ave
New York, NY 10016
(800) 323-3136
dentatus@dentatus.com
www.dentatus.com



Dentatus AB
Jakobsdalsvägen 14-16
S-126 55 Hågersten, SWEDEN
TEL +46 8 645 27 75
sweden@dentatus.com

AVAILABLE DIRECTLY FROM DENTATUS